

## Day 1 – January 15th



Material for sialendoscopy  
Shirish Ghan, India



Outsourced sterilization of sialendoscopy materials is possible  
Torti El Zein F, De Pinho M, Dusolcy I, Mathieu I, Pueyo C,  
Tuyindi N, Marty L  
Florinda Torti Elzein, France  
Chef de service ORL et chirurgie thyroïdienne  
Centre Hospitalier Marne la Vallée

For the HAS (higher sanitary authority) recent models of sialendoscopes must be sterilized and a very frequent breakage of optical fibers during manipulations related to sterilization occurs. This fragility of autoclaving sialendoscopes is problematic, but strongly advised by HAS in order to mitigate the risks of hospital-acquired infections.

Therefore a specific transportation circuit to be followed, staff designated for the cleaning and traceability sheets were set in place between the surgery department, the sterilization department and the head and neck surgery department.

### DISCUSSION:

During 2018 and 2019 were carried out 27 procedures.

Between the 6th and the 7th procedure a case was identified due to a transport problem even though before and after autoclaving the material was labelled compliant.

This has allowed to improve precautionary measures during transport. Since then 20 procedures have been carried out on a distance of approximately 30 km between the sterilization department and the surgery department without breakage.

### CONCLUSION

It is possible to carry out an effective sterilization in an autoclave even in the case of a distance between the sterilization department and the surgery department of more than 30 km.



Our experience starting a sialoendoscopy program, Clinica Alemana, Chile

**Luis Zanolli**, Hugo Rojas, Fabio Valdes, Felipe Capdeville, Katherine Lozano, Arturo Madrid

### **Objectives**

We want to communicate our experience with the implementation of this technique for the last 2 and a half years, presenting lessons learned, setbacks and preliminary results.

### **Methods**

From April 2017 to November 2019 we have performed 46 procedures. Diagnosis and treatment of stones, stenosis, and recurrent as well as post-radioactive sialoadenitis.

### **Results**

During 2017 and 2018 only 20 cases were performed, but since 2019 we observed a double fold increase in our numbers.

24 cases of lithiasis, 20 of sialoadenitis, 1 stenosis and 2 post radioiodine

The success rate was 82%, with one serious complication due to duct injury that required a submandibulotomy.

### **Conclusions**

- Results and early follow up are presented here.
- We have seen a progressive internal and external referral due to a high success and low complication rate.



Sialendoscopy - how I learned to do it  
Fiona Wong, Hong Kong

Dr. Fiona Wong was graduated from medical school in The Chinese University of Hong Kong and she completed ENT training at Pamela Youde Nethersole Eastern Hospital. She currently serves as an associate consultant and she chairs the Salivary Gland Disease Division as well as the Sleep Apnea Surgery Division in the hospital.

After attending the International Sialendoscopy Course with mini-fellowship by Prof. Marchal in 2013, I am truly inspired. With great enthusiasm in performing salivary gland surgery particularly sialendoscopy, I set up a protocol in management of salivary gland problems in my hospital from diagnosis, preoperative investigations to procedural guidelines in performing sialendoscopy. I encountered difficulties at the start up and found some pearls and pitfalls, therefore I would like to share my learning experience in this technique.



How to improve further after we start  
Michal Zabrodsky, Czech Republic



Salivary gland diseases and sialendoscopy in Georgia  
Gaga Kuliashvili, Georgia

Population-based analysis of inpatient salivary gland surgeries has never been done before in Georgia.

Aim of this nationwide statistical analysis of 2016 to 2019 was to estimate frequency of salivary gland surgeries throughout Georgia, especially due to sialadenitis and sialolithiasis. It was important to evaluate possibility of developing Sialendoscopy among surgical interventions done for salivary gland diseases.

In data provided by the National Center for Disease Control and the National Center for Public Health, classification is based on ICD-10 codes and surgeries are according to NCSP codes. According to the data, the most frequent indication of salivary gland surgeries per 100 000 population are salivary gland benign tumors, sialolithiasis, malignant tumors and sialadenitis. The difference between the incidence of salivary gland disease in males and females and the mean age of cases is also calculated.

Hindering factors in doing the Sialoendoscopy in Georgia mainly are related to reimbursement situation and mistrust to new methods of treatment.

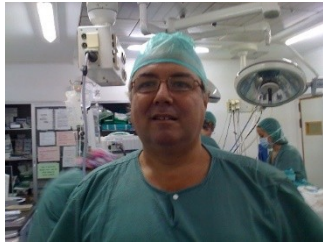

Those things I have learned as a beginner in sialendoscopy

Tsun-Min Lu, Hsinchu MacKay Memorial Hospital, Taiwan

Patient selection is important for beginners. Distal submandibular glandstone cases under general anesthesia would be a good start. Identifying and dilating the papilla are the rate-limiting step in sialendoscopy and using microscope is helpful. Be gentle and patient to papilla because bleeding or papilla trauma will result in more time-consuming consequences. Based on previous studies and experts' opinions, pediatric feeding is a good choice of sialstent, with less dislodge rates and irritation. If beginners cannot dilate the papilla enough to insert pediatric feeding tube, the IC catheter can be an alternative choice, as the outer diameter of IC catheter is smaller and the inner diameter is still large enough for saliva flow. However, the length of IC catheter is not long enough for hilar cases. Sialstent fixation with 5-0 nylon is adequate. In general consensus, the indwelling time for sialstent is at least 2 weeks.

About the wound repair, there are limited studies to explore whether ductoplasty or oral mucosa repair is necessary. In our experience, the wound recovered well in those cases we only placed sialstent and spared ductoplasty or oral mucosa repair.



Tips and tricks in sialendoscopy  
Carlos Cenjor, Spain

The beginnings of any technique require a learning curve to a critical point from which the accumulated experience allows to securely protocolize the procedures

After 300 procedures of protocolized sialoendoscopy we have drawn some conclusions referring to:

1-material

2-Indications

3-technical considerations grouped in "tips and trucks" that have allowed us to improve in the procedures we carry out today.



Sialendoscopy in Lithuania - first year experience  
Nora Ulozaitė-Staniene, Lithuania

Sialendoscopy is a relatively new procedure in Lithuania, currently with only one medical center providing this type of treatment. This study is a one-year experience in Lithuanian University of Health Sciences Department of Otorhinolaryngology. During this period, we performed 70 sialendoscopies, covering all indications for this procedure: sialolithiasis, autoimmune salivary diseases, radioiodine induced sialadenitis, juvenile recurrent parotitis, chronic sialadenitis. Furthermore, diagnostic and treatment protocol was developed including ultrasonography, number of swelling episodes, visual analog scale for patients complains (severity of pain during swelling episode, xerostomia affecting quality of life), xerostomia questionnaire with a follow up of 3- and 6-months post sialendoscopy. Our early results show success rate of more than 90%.



Startup Sialendoscopy Practice - Lessons Learned  
Associate Professor Bernard Lyons MBBS FRACS  
Director of ENT Head and Neck Surgery/Skull Base Surgery  
St. Vincent's Hospital, Melbourne Australia

This paper presents the experience of one practitioner in the development of a Sialendoscopy practice over 5 years. The results of over 50 cases will be presented. The emphasis of the paper will be on problems encountered related to learning technique, management of equipment and justifying the technique in a country with no formalised reimbursement for Sialendoscopy.



Sialendoscopy in Egypt since 2009  
Emad Magdy, Egypt



Epidemiology of obstructive salivary gland diseases  
Takeshi Matsunobu, M.D, Ph. D.  
Department of Otolaryngology-Head and Neck Surgery, Nippon  
Medical School, Tokyo, Japan

Obstructive sialadenitis is the most common non-neoplastic salivary gland problem. Patients typically present with a history of recurrent painful peri-prandial swelling ('mealtime syndrome'), often complicated by infection, as evidenced by purulent discharge from the papilla. Obstructive sialadenitis was historically thought to be due only to stones, but current practice shows an important number of strictures or stenosis for which data are more scarce.



Stones composition & characteristics: scientific evidence and clinical pearls  
Rohan Walvekar, USA



**Title:** DOES SALIVA COMPOSITION AFFECT THE FORMATION OF SIALOLITHIASIS?

Stine Attrup Schrøder, MD, Department of Otorhinolaryngology, Nordsjaellands University Hospital, Hillerød, Denmark

Preben Homøe, MD, Ph.D, DMSc, Department of Otorhinolaryngology and Maxillofacial Surgery, Zealand University Hospital, Lykkebaekvej 1, DK-4600 Koege, Denmark

Niels Wagner, MD, Department of Otorhinolaryngology, Aleris-Hamlet Hospital, Ringsted, Denmark

Allan Bardow, Ph.D, DDS, Department of Oral Medicine, Dental School of Copenhagen, University of Copenhagen, Copenhagen, Denmark

### **Abstract**

**Objective:** Sialolithiasis is one of the most common diseases of the salivary glands with an incidence between 2.7-5.7/100,000/year. The aetiology of sialolithiasis is debated, and saliva composition may affect the formation of sialolithiasis. Thus, the aim of this study was to examine whether the salivary inorganic composition in patients suffering from sialolithiasis differs from that of healthy controls, and whether the salivary inorganic composition changes after surgery for sialolithiasis. Further, the study evaluates if salivary flow is affected by sialolithiasis and if the flow normalises after surgical removal of the sialolith.

**Methods:** The study included 40 patients who were all characterized by the following: suffering from sialolithiasis and undergoing surgery for sialolithiasis by either sialpodoscopy, sialodochotomy or by a combination of these procedures. The patients were matched to 40 healthy controls. Also, patients were examined before and after sialolithiasis surgery;

controls were only examined once. The study assessed the flow rate of unstimulated whole saliva and the inorganic composition of saliva.


**Results:** Patients' salivary flow prior to surgery was significantly lower compared to that of healthy controls but equalised after surgery. Prior to surgery, patients' saliva exhibited higher concentrations of e.g. calcium, magnesium and phosphorous as compared to that of the healthy controls. The concentration of most of the ions remained high after sialolithiasis surgery.

**Conclusion:** Sialolithiasis patients had reduced salivary flow prior to surgery, but the salivary flow normalised after surgery, also, sialolithiasis patients had increased salivary concentration of the ions that constitutes the main inorganic phase of most sialoliths, and this may confer a risk for developing sialolithiasis.

### **Key words**

Sialolithiasis, Sialoendoscopy, Oral health

No preferences between oral or poster presentation.



### **Transroal Ultrasound in the Diagnosis of Salivary gland stone**

Woojin Cho

Withsim Clinic

Department of Otolaryngology-Head and Neck Surgery

Ultrasonography has been widely used in the management of salivary gland stone. Conventionally transcervical scanning is used to diagnose a pathology of major salivary glands and ducts. However, there are limitations such as hard to detect tiny intraductal lesion, which are especially located nearby duct orifice. And conventional scanning to trace and visualize salivary gland duct needs more experience than other area of neck due to its complex sonographic anatomy.

Specially designed transducer for intraoral scanning can overcome these limitations. Transoral ultrasound(TOUS) using intraoral transducer can be done directly from the oral mucosa overlying salivary gland duct and orifice. It enables us to localize a target stone before surgery and also check whether there is remnant lesion or not. Furthermore, combined scanning with both intraoral and conventional transducer could increase the accuracy of detecting tiny and multiple stones.





**NON CONTRAST CT/MRI SIALOGRAPHY: THE ALEXANDRIA RADIOLOGY SALIVARY DUCT ASSESSMENT PROTOCOL**

**Dr. Omneya Gamaleldin, lecturer of radiodiagnosis, Alexandria university**

**Abstract:**

When it comes to imaging of salivary ductal system, we come to talk about sialography. Sialography includes either conventional or MRI sialography. Conventional sialography is rarely employed today because it is invasive and uses contrast material. MRI sialography is performed without intravenous or intraductal contrast material, non invasive, painless and uses the natural contrast medium saliva. Non contrast CT is more sensitive than MRI in detecting the presence and number of stones. That is why our Alexandria protocol combines the use of non contrast CT to better detect presence and number of stones and then MRI sialography to draw a roadmap for the surgeon about the main duct and intraglandular ducts regarding exact location and size of stones, dilatations; strictures and ruptures if any. These information guide the surgeon about the proper choice of management whether endoscopic only or combined endoscopic and open approach. Again, this reflects on the patients having better outcome; small incision and most important of all preservation of the salivary glands.



Riitta Saarinen

Local anesthesia (LA) or local anesthesia with sedation (LAS) is the most common anesthetic method in 89% to 96% of all sialendoscopies in Finland. With LA/LAS side effects of general anesthesia such as nausea, dizziness, confusion and bladder problems can be avoided. In addition, patients are in most cases discharged from the hospital earlier. LA also allows a safe procedure to those who have an elevated ASA (American Society of Anesthesiologists) status scores.

In our recent study 89 patients estimated their sensations about the LA/LAS sialendoscopy postoperatively. Over half of the patients experienced major or moderate nervousness

before the operation but the procedure itself was well-tolerated. The majority of patients (87%) estimated the level of discomfort and pain mild or none during the procedure. Patients who underwent sialolith removal through a transoral incision estimated the level of discomfort and pain higher than others but in total 97% of the patients would agree to a LA/LAS sialendoscopy again in the future if necessary.

We recommend LA/LAS for majority of adult patients. However, if the procedure is expected to be complex or long-lasting, general anesthesia should be considered. There is also some evidence emerging on pediatric sialendoscopy under LA. In pediatric patients LA/LAS is an option worth considering in cooperative children and will likely become more common in the future.



TITLE: LASER ASSISTED SIALENDOSCOPIC LITHOTRIPSY- A REVIEW OF 50 CONSECUTIVE CASES AND ENDOSCOPIC FOLLOW UP.

AUTHORS:

Dr. Varun Rai Consultant ENT, Sir Ganga Ram Hospital, New Delhi, India

Dr. Uday Monga, Consultant ENT, Sir Ganga Ram Hospital, New Delhi, India

Dr. Jatin Verma Clinical Assistant ENT, Sir Ganga Ram Hospital, New Delhi, India

Dr. Simrandeep Singh Jathol Resident ENT, Sir Ganga Ram Hospital, New Delhi, India

#### ABSTRACT:

Sialendoscopy has now emerged as the gold standard in treating obstructive sialolithiasis which was initially reserved for floating stones in the duct and was used in conjunction with oral surgery for larger impacted stones. However, with the extended use of laser sialolithotripsy entering the mainstream, gland preservation has become the norm rather than the exception. With any heat producing device like the laser, it has its own set of problems and shortcomings which has to be addressed in addition to the initial pathology. We present a series of 50 patients operated for salivary stones between July 2017 and June 2019. The stone sizes ranged from 8.9mm-3.6mm. 84%(n=42) of the stones were present in the submandibular gland hilar area and 16%(n=8) were in the parotid gland. Successful fragmentation was achieved in a single sitting in 41 cases (82%) where the initial size of stone

was the limiting factor and two sittings were required in 8 cases and one case required 3 sittings.

All patients reported improvement in symptoms with occasional postprandial swelling seen in only 22% of cases. However, follow up endoscopic evaluation showed stenosis in 64% of the cases and residual stone fragments in 76% of the cases. The stenosis and residual stones were managed during the check endoscopy in the OPD setting.

Due to the huge discrepancy between the symptom scoring and the endoscopic scoring in the post operative period we advocate that laser sialolithotripsy should only be used with caution and rigorously followed up with serial endoscopies. Akin to nasal endoscopic follow up after a sinus surgery, depending on an office based sialendoscopic evidence should be considered routine to effectively manage sialolithiasis.



### **Pneumatic Lithotripsy versus Holmium Laser-Assisted Lithotripsy in the Management of Submandibular Sialolithiasis**

#### **Abstract**

Sialolithiasis is the cause of about 60%-70% of obstructive salivary gland diseases, and it is found in the submandibular gland by approximately 80%. Using sialendoscopy, stones under the size of 4 mm in the Wharton's or Stenon's ducts may be caught and extracted by baskets or other tools by approximately 80%. However, the stones of this size constitute 15% to 20% of all cases. It is possible to use sialendoscopy or combined approaches to extract stones that are larger after breaking them up and separating them into smaller particles. In this presentation, the author aimed to explain the indications, treatment outcomes and reliability levels of the intraductal pneumatic lithotripsy (IPL) and holmium laser-assisted lithotripsy (HLL) methods that are used to sialendoscopically separate stones into smaller pieces in submandibular gland sialolithiasis (SMGS) patients. And also, the author will present the personal experience about the topic and will describe the advantages and disadvantages of these two techniques in SMG stones.

## ABSTRACT

### SIALENDOSCOPY-ASSISTED TRANSORAL AND TRANSFACIAL REMOVAL OF PAROTID STONES

**Pasquale Capaccio, MD**

Department of Biomedical, Surgical and Dental Sciences – University of Milan –  
Fondazione IRCCS Ca' Granda Ospedale Maggiore Policlinico, Milan, Italy

Conservative management of parotid stones is nowadays based on different techniques. Extracorporeal lithotripsy has been used in the past especially for intermediate stones (3 to 7 mm) but it is almost abandoned because of unavailability of lithotripters. Interventional sialendoscopy has emerged as the best option technique for all mobile and small to intermediate stones (by means of baskets and laser lithotripsy). Large and impacted stones or deep intraparenchymal stones can be successfully managed by means of sialendoscopy-assisted surgical techniques. Two different sialendoscopy-assisted surgical pathways can be followed to reach the parotid stone: the transoral approach permits to reach all stones located in the main Stensen's duct up to its proximal third; the transfacial preauricular approach permits to reach all parenchymal stones and mid to proximal duct stones. A combined CT navigation-guided procedure can be further proposed for deep and unpalpable parenchymal stones. Both sialendoscopy-assisted transoral and transfacial approaches will be illustrated by focusing the attention on indication, safety, and efficacy. Based on the experience acquired on the minimally invasive and conservative approach to parotid stones, sialendoscopy-assisted transoral and transfacial surgery for parotid stones represent an integral part, together with interventional sialendoscopy and lithotripsy techniques, of the therapeutic strategy aiming at functional preservation of the parotid gland.



#### **The mini-incision combined “sialendoscopic/microscopic” sialolithotomy approach for large parotid duct stones**

**Presenter: Emad A. Magdy, MD, PhD (ORL)**

Professor, Department of Otorhinolaryngology-Head & Neck Surgery,  
Faculty of Medicine, Alexandria University, Alexandria, Egypt.

#### **2<sup>nd</sup> International Sialendoscopy Conference Program assigned date & time:**

Wednesday 15<sup>th</sup> January (14:00-16:30 Session)

Under Minimal Invasive Techniques: Parotid (7 min.)

#### **Abstract:**

Sialendoscopy has revolutionized management of salivary sialolithiasis making stone extractions with gland preservation possible in most cases. However, managing larger parotid stones (>5mm) can still be a challenging problem. Endoscopic options necessitate, either stone fragmentation most commonly using a holmium laser or use of a combined “hybrid” approach incorporating an external incision.

Laser fragmentation can be quite a tedious time consuming maneuver that carries risk of both ductal as well as scope injury. Combined parotid approaches are traditionally described using a standard face-lift parotidectomy incision with creation of a U-shaped SMAS flap

lateral to the duct. This approach although saves the gland carries a parotidectomy operation surgical burden thus skews from the essence of minimal invasive surgery. Alternatively, a direct transfacial incision over the duct has been proposed; however, this can be esthetically unpleasing for most patients.

We describe our experience in performing combined parotid approaches for stones > 5mm using a minimally invasive “mini-parotid incision” in the posterior aspect of the tragus then curving around the ear lobule after stone localization using parotid sialendoscopy. Open approach sialolithotomy at the site of endoscope illumination as well as later duct repair are done meticulously under microscopic control ensuring safe and secure parotid duct management. Technical details as well as case reviews are described in full.



### **Decision making of management of L2 L3 Submandibular Stones**

**Presenter: Siu-Kwan NG**

The options of completely removing L2/L3 submandibular ductal stones include:

1. Laser fragmentation with sialendoscopic removal
2. Combined sialendoscopic/ open approach
3. Submandibular gland excision

In order to obtain proper patients' informed consent and better surgical preparation, the pre-operative determination of the choice of approach is very important. This is because the operative time, required equipments, associated risk and morbidity are vastly different among the 3 approaches.

The key factors to consider include:

1. Anatomy of patient
2. Location of stone using SK angle as a reference point
3. Size of the duct
4. Size of stone
5. Palpability of the stone

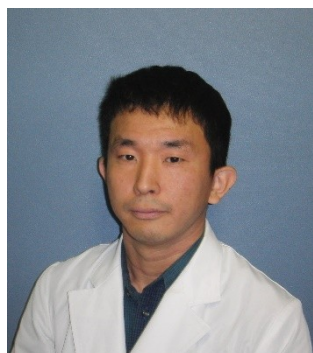The plain CT scan is a very useful assessment tool.

Sialendoscopy assisted combined transcutaneous SM stone retrieval with gland preservation



Aleksandar Aničin

Transcutaneous parotid stone sialendoscopy assisted retrievals are well established and accepted, but this is not the case with submandibular sialolithiasis. The reason for this position is that the submandibular gland resection is by far less demanding than a parotidectomy. Having a relatively low complication rate, submandibular gland resection is still deemed a gold standard procedure if a sialendoscopic or combined transmucosal approach was unsuccessful in patients with far proximal sialolithiasis. The ultimate option for submandibular gland salvage, combined transcutaneous sialendoscopy assisted submandibular stone retrieval, is not a generally accepted procedure, because of doubting into its long-term success, yet sharing some possible complications with a total gland resection. Regardless this opinions, there have been some recent reports on transcutaneous sialendoscopy assisted proximal submandibular stone retrievals with submandibular gland preservation, which can present a solution of selected cases, especially if transluminal lithotripsy is not feasible. We present our experience with sialendoscopy assisted combined transcutaneous submandibular stone retrieval with gland preservation.



Sialendoscopy-assisted transoral removal of submandibular stones in the transitional region  
Shinichi Esaki, Yuki Hamajima  
Nagoya City University

Most of salivary stones are found in the submandibular glands and/or Wharton's ducts. For the patients with submandibular stones in the transitional region, percutaneous removal of the submandibular glands was performed in our hospital. Now transoral removal of the submandibular stones is usually selected for those patients in our hospital, and assistance by sialoendoscopy has increased the successful rate of removing stones. This time, we will present our approach for removing submandibular stones in the transitional region. When the stone is smaller 5 mm in diameter, the stone can usually be removed with sialoendoscopy alone. Otherwise, the stone can be removed from oral cavity with assistance of sialoendoscopy. Assistance of sialoendoscopy helped us to speculate the location of the stone. This approach is useful since submandibular glands can be preserved.




From OTSUKA Yuichiro - Japan

Title: Transoral surgery (intraoral incision) and sialendoscopic surgery for submandibular hilar stones and deep wharton ducts stones in our hospital.

**Abstract:**

In Japan, most hospitals select total submandibular gland excision to submandibular hilar stones and to deep wharton ducts stones. But most salivary stones are smaller than 1cm, so gland excision may be considered invasive. For less invasive surgery, we perform sialendoscopic surgery and transoral surgery (intraoral incision) or with both (combined approach surgery). We do not have Ho-YAG Laser, so the surgical indication of sialendoscopic surgery is restricted and transoral surgery plays an important role in our hospital. From April 2016 to September 2019, we performed 51 surgeries of deep wharton duct stones and submandibular hilar stones. 11 sialendoscopic surgeries, 22 transoral surgeries (intraoral incision), 17 surgeries with combined approach and 1 submandibular gland excision were performed. We failed to remove the stone in 4 cases and small fragments were left in 8 cases. There were some slight complications with sialendoscopic surgeries, such as submandibular swelling and wound pain. Conversely transoral surgeries and combined approach surgeries caused many complications, submandibular swelling(26 cases), lingual numbness and palsy(21 cases), wound pain(31 cases), nose bleeding due to nasal intubation, floor of mouth swelling, lock jaw, pharyngeal lateral swelling, laryngeal swelling, lip numbness, and taste disorder. There were no case of airway distress.



**Multidisciplinary approach for the management of multiple submandibular stones**

Jeong Kyu Kim,

Catholic University of Daegu, Daegu, South Korea

We reviewed our institution's experience with multidisciplinary approach for the management of multiple submandibular stones.

**Methods**

Clinical data were retrospectively reviewed on patients who were treated for multiple submandibular stones from January 2015 to August 2019. Multiple stones were detected in 29 of 446 consecutive patients of submandibular stones.

**Results**

Twelve (41.4%) patients had 2 stones, 10 (34.5%) patients had 3 stones, and 7 (24.1%) patients had more than 3 stones. Eight (27.6%) patients were treated only by transoral surgery, while 21 (72.4%) patients were treated by transoral surgery and sialendoscopy. In 19 patients, sialendoscopy was performed to remove proximal stones through the site of transoral surgery for the distal stones. In 2 patients, sialendoscopy was performed to remove

the distal stones and transoral surgery was performed for the proximal stones. In 26 patients, all of multiple stones were completely removed. The 4 residual stones in 3 patients were sized mean 4.0 mm (range; 2.5 – 4.6) and located in the parenchyme

#### Conclusions

Sialendoscopy can be usefully applied to remove the proximal stones through the site of transoral surgery for the distal stones in patients with multiple submandibular stone



Minimally invasive surgery for the sialolithiasis using sialendoscope in Japan

Takeshi Matsunobu, M.D, Ph. D.

Department of Otolaryngology-Head and Neck Surgery, Nippon Medical School, Tokyo, Japan

Endoscopic management of inflammatory and obstructive pathology of the major salivary gland ductal system could provide significant advantages, such as avoidance of an external scar, gland preservation, endoscopic visualization of the pathology, same-day surgery, and faster recovery times as opposed to the need for inpatient stay. Most important, sialendoscopy largely avoids injury to the hypoglossal nerve, lingual nerve, marginal mandibular nerve, and facial nerve. Thus, there has been an increasing interest in this procedure, with many hospitals in Japan and around world adopting sialendoscope into their practices.

We have initiated sialendoscopy program to treat the sialoliths of the major salivary glands since 2009. We present a retrospective observational study of our patients who were treated at our institution. Our goal was to report our initial experience and challenges faced with interventional sialendoscopy.

Sialendoscopy is a minimal invasive surgical technique which allows extraction of the stones by a basket under endoscopic view. Interventional sialendoscopy allows for extraction and fragmentation in the majority of cases of sialolithiasis, and there is no need for removing salivary glands.



Our experience of sialendoscopy in Department of Otolaryngology-Head and Neck Surgery, Asahikawa Medical University.



Miki Takahara  
Department of Otolaryngology-Head and Neck Surgery,  
Asahikawa Medical University

We are trying removal of sialolithiasis by using sialendoscopy since 2010, and I would like to show our experience and clinical outcome of our cases. Our fundamental operative procedure starts to make new aperture formation of Wharton duct after removal of sublingual gland for easy insertion of sialendoscopy and prevention of postoperative sublingual ranula.

We experienced 103 patients with sialolithiasis of submandibular gland who underwent removal of the stone by using sialendoscopy from 2010 to 2018. The patients were composed of 43 male and 60 female aged 3-88 years (median 38 years). Affected side was right in 58 (56%) patients, and most stones were located at the hilus in 93 (90%) patients. The stone size ranged from 2.0 to 20.0 mm (median 8.3 mm). Submandibular stones were removed by sialendoscopy alone in 41 (39%) patients and combined approach in residual 62 (61%) patients. The operative duration was ranged from 17 to 195 min (median 64 min). In regard to postoperative complications, submandibular gland swelling and lingual nerve paralysis were seen in 32 (31%) and 17 (17%) patients, respectively. However, those improved within few months after operation except one case. According to these findings, sialendoscopy is useful for removal of the sialolithiasis without neck incision.



Our experience of sialendoscopy for submandibular gland stones  
Takahiro Suzuki  
Tohoku Medical and Pharmaceutical University

In our hospital, we have mainly used sialendoscopy for the cases of submandibular gland sialolithiasis with non-palpable ductal stones or hilar stones. We did not use the laser instrument. There are 43 cases for whom we have used sialendoscopy over the past 4 years and 6 months. The stone sizes were 2–15 mm (median 5 mm). Regarding the location of stones, 10 cases showed stones in the Wharton's duct, 29 in the hilum of the gland, and 4 in the gland. We successfully extracted the stones via oral cavity for 39 cases (91%) except for 4 cases with intraglandular stones. As postoperative complications, transient submandibular swelling was observed in 8 cases, transient lingual nerve palsy in 2, ranula in 2, and submandibular gland abscess in 1. Sialendoscopy seems to be a safe and useful method that can facilitate stone removal via the oral cavity.

**Abstract n° 2 : Large parotid stone on pediatric case**

A 7-years old girl was referred to the office by ENT colleague for several infectious episodes on the right parotid gland.

Clinical examination revealed stony induration 1,5 cm ahead of the right tragus, very superficial under the skin, with sticky saliva and debris at the ostium of Stensen's duct.

CT scan confirmed a 7 x 5 mm parotid stone, with very high calcic density, subcutaneous, 2 mm under the skin.

Combined approach using facial mini-lift guided by endoscopic identification was proposed due to expected failure of totally endoscopic approach in such case.

Right mini-lift incision was drawn on the skin and subcutaneous infiltration with dilution of lidocaine/adrenaline was performed prior to sialendoscopy.

Surprisingly, the stone was found very easily in the ductal system and totally endoscopic procedure with Holmium laser fragmentation was performed successfully.

Discussion on indication and feasibility of totally endoscopic versus combined approaches for parotid stones.

Kind regards,

Dr Julien HANSS

ENT surgeon, Private Practice

Paris, France



### **A case of parotid duct stone invisible on the CT scan**

Ji Won Kim

<sup>1</sup>*Department of Otolaryngology, Inha University, College of Medicine, Incheon, Republic of Korea*

#### **Abstract**

Sialolithiasis of parotid gland is rare than parotid duct stenosis. The vast majority of stones involve the submandibular gland, with only a small proportion involving the parotid gland. The glands may be evaluated with imaging modalities including; ultrasound, CT and MR sialography. This patient with recurrent right parotid postprandial swelling was suspicious for ductal stenosis. Because CT scan showed asymmetrical diffuse enlargement of right parotid gland without stone, and MR sialography demonstrated the severe segmental stenosis in intraglandular portion of main duct. However, we found 2mm sized stone on 1st branch of intraglandular duct on sialendoscopy. We should consider the radiolucent stone and evaluation with the ultrasound.



### **An unusual case of calcular parotid duct obstruction: How can preoperative imaging help?**

**Presenter: Hesham Zoheir, EGYPT.**

## **Abstract**

Advances in sialendoscopy and minimally invasive approaches in management of salivary ductal pathology have concurrently increased the need for multimodality imaging in accurate diagnosis of peculiar cases.

Hereby, a reported case is a 35 year old male patient presenting with typical symptoms of salivary ductal obstruction including intermittent pain and left parotid swelling related to meals, as well as localized tenderness of the involved gland.

The patient had a CT scan done which showed a single ductal stone, however, suspicious findings were also noted distal to the stone. Complementary ultrasonography was performed showing intraductal debris and no definite distal pathology.

MRI sialography was then performed which showed findings undiagnosed by previous imaging techniques, and revealing a hidden culprit. He was managed by sialendoscopy which confirmed the peculiar finding diagnosed by the MRI sialogram. Case details will be presented demonstrating the preoperative imaging advantage of using MRI sialography.



## **Unusual Finding in a case of Submandibular Gland Stones.**

### **Ahmed Elbana**

ORL-H&N Department, Alexandria University, Alexandria, EGYPT.

ORL-H&N Department, Security Forces Hospital, Riyadh, SAUDI ARABIA.

## **Abstract:**

**Background and Objectives:** Salivary gland Stones (also termed salivary calculi, or Sialolithiasis), is a common finding where a calcified mass forms within a salivary gland or its duct, usually the submandibular gland is the most commonly affected gland. In most of cases it's easy to diagnose by obtaining a Computed Tomographic scan (CT) without contrast, but few conditions may mimic the radiopaque appearance of the stones. In this study, we present one of these conditions with a submandibular stone on one side and the tip of an elongated styloid process on the other side, which in some CT cuts may be mistaken as another stone.


**Case:** A 34 years old male patient presented to the outpatient clinic with history of recurrent attacks of Right submandibular swelling and Left throat pain and foreign body sensation. CT scan was done for the patient and revealed a Right submandibular radiopaque shadow presenting a submandibular gland stone, and another radiopaque shadow on the left side which (after reviewing all the CT cuts) turned out to be left elongated styloid process.

**Discussion:** Approximately 4% of the general population have an elongated styloid process, and of these about 4% give rise to symptoms of Eagle syndrome. Eagle syndrome (Elongated Styloid process) was first described by an American otorhinolaryngologist, Watt Weems Eagle, working at Duke University in North Carolina, USA. He first published his data in 1937 with a series of 200 patients presenting with symptoms of a calcified stylohyoid ligament or elongated styloid process. These symptoms include a pharyngeal foreign body sensation, dysphagia, pain on head rotation, otalgia, dizziness and headaches. The symptoms are attributed to impingement of the glossopharyngeal nerve as it runs close to the styloid process and calcified ligament. An elongated or calcified stylohyoid ligament does not necessarily indicate Eagle syndrome. The diagnosis is made on the basis of history and exacerbation of pain on palpation of the tonsillar fossa.

**Conclusion:** Not all radiopaque shadow on a CT scan represent a stone of salivary glands, a thorough review of all the cuts and also the clinical history and examination of the patient will help to differentiate any other rare condition that may mimics the appearance of a stone.

**Conflict of interests:** The authors have no conflicting financial interest.

**Presenter's biography:** Dr Ahmed M. Elbana , MBBCh , MSc of ENT , Alexandria, Egypt, MRCS (ENT) Royal College of Surgeons Edinburgh, UK, Fellow of European Board of ORL (EBEORL), ENT Specialist in Security Forces Hospital, Riyadh, KSA



Avulsion of primary branch of Wharton's duct during sialendoscopic basket procedure.

Jeong Kyu Kim

Catholic University of Daegu, Daegu, South Korea

A 10 years old boy suffered from recurrent right submandibular swelling for 1 year. CT and ultrasonography showed 4 mm sized stone on hilum. Sialendoscopy revealed mobile stone in the primary branch of Wharton's duct. During basket retrieval, stone was stuck at the primary bifurcation site and then pop out with ductal mucosal strip. Second look sialendoscopy revealed bleeding and injured primary branch of duct. Patient had mild postprandial submandibular swelling for 8 days after surgery. At 1 month follow up after surgery. ultrasonography showed dilated proximal part of Wharton's duct but the patient had no obstructive symptom.

**Sialendoscopy- complication: broken dormia basket**

D. Greger  
ENT- Dept., University Medical School Graz, Austria

**Abstract:**

From November 2006 - December 2019 498 sialendoscopies were performed. Apart from 1 broken dormia basket no major complications occurred in this series. Special problems and difficulties in performing sialendoscopy will be discussed.



**Long standing large parotid sialoceles with multiple large stones: Can we save the gland?**

**Authors:**

**Mahmoud Seifelnasr, Muhammad Fawzi, Omneya Gamaleldin, Emad Magdy.**

**Presenter: Mahmoud Seifelnasr**

**Abstract:**

In the last two decades, the focus of treatment in salivary gland obstructive pathologies has shifted to gland preservation, whenever possible, with sialendoscopy used as a minimally invasive diagnostic as well as therapeutic method of management.

Herein we discuss a challenging case of a 54 years old female patient presenting with a large right parotid swelling with a long history of recurrent parotitis increasing in size during meals. On examination, the right parotid swelling was cystic and non-tender.

Preoperative imaging (Non contrast CT/MRI sialography) showed a well defined 2.6 x 1.7 cm cystic lesion overlying the masseter arising from the right main parotid duct (sialoceles) and containing two large stones measuring 9 and 7 mm in length. Another more distal obstructing 2.4 mm stone was found in the main parotid duct, which was characteristically dilated proximally with distal duct collapse.

In an attempt to save the gland, sialendoscopy was done under general anesthesia. Intraoperative findings as well as decisions taken for case management thereafter are described in details and correlated with the preoperative imaging findings.



Hesham Hasan

Title: Recurrent sialolithiasis: Myths, fiction & facts

Abstract :

Sialolithiasis is the most frequently encountered disease entity of the salivary gland, affecting as much as 60 cases per million per year, with an overall 1.2% prevalence rate. Despite being rare, but their recurrence following surgical intervention is said to be as high as 8.9%, which would impose not only an agonizing entity for the patient but also an equally distressing phenomena for the treating physician. In our current study, we aim to review the potential mechanisms causing stone formation and mediating subsequent recurrence ranging from mechanical, chemical, inflammatory and neurohumoral causes. Prognostic factors highlighting potential higher recurrence rate following intervention will be discussed. Finally, authors floating ideas about this floating topic will be raised and discussed.



### **Surgical management of plunging ranulas**

Bernard C.S. Whitfield

#### **Abstract:**

**Background:** Plunging ranulas are rare mucous extravasation pseudocysts that arise in the floor of the mouth and pass into the submandibular space of the neck. The aim of this study was to investigate the diagnosis, surgical management and outcomes of patients with a plunging ranula at our institution in South East Queensland over a 10-year period.

**Methods:** A retrospective analysis of adult patients diagnosed with and treated for plunging ranula between 2006 and 2016 at Logan Hospital was conducted. Patient demographics, preoperative investigations, surgical management and post-operative outcomes were collected from medical records.

**Results:** A total of 18 adult patients were treated for plunging ranula. Of the 18 cases, 17 were treated via transoral excision of the sublingual gland. The mean age at presentation was 28.8 years with a 3:1 female to male predominance. Fifty-six percent of patients were of Polynesian descent. The success rate was 94% with only one patient experiencing recurrence and requiring re-excision of remnant sublingual gland tissue.

**Conclusion:** This study demonstrates that excision of the sublingual gland is an effective and safe treatment for plunging ranula.



Dubai Congress. CHOSSEGROS C et al. lectures

3. Salivary side effects after radioiodine treatment for differentiated papillary thyroid carcinoma: a long-term study.

Chossegros C, Graillon N, Le Roux MK, Taieb D, Foletti JM

Oral & Maxillofacial Department, Conception University Hospital. 147 bd Baille 13005 Marseilles, France. [cchossegros@ap-hm.fr](mailto:cchossegros@ap-hm.fr)

**Objectives.** Salivary side effect after radioiodine treatment is still a main concern. Although many studies focus on short-time side effects and preventive treatment, almost none studied long-term side effects over 2 years. The objective of this study was to assess radioiodine long-term salivary side effects after radioiodine treatment for differentiated papillary thyroid carcinoma (DPTC) and compare it to short term morbidity in the same population.

**Methods.** 413 patients were included after responded for the first time to a 13 items questionnaire in 2013 and to the second time in 2019. We only retain patients which were initially given a single dose of I<sup>131</sup> iodide capsules, 100 mCi (3.7 GBq, Covidien plc, Dublin, Ireland) in treatment for DPTC. After questionnaire counting, data were filled and compared between the same population in 2013 and 2019 using McNemar's match test for nominal data and Wilcoxon test for ordinal data.

**Results.** Among 408 patients who responded in the first instance to the first questionnaire in 2013, 239 (58%) patients could be reached by phone or mail. 170 patients (79%) respond to the questionnaire and eight were excluded (two died, one from DTPC and six went through iterative I-131 therapy). There were 36 males (22.2%) and 126 females (77.7%), sex ratio was 0.29 and the mean age was 62.4 years ± 12.5 (min 27, max 86).

**Conclusion.** Our within-population comparison between short and long-term salivary side effect found a significant decrease of all symptoms (swelling, discomfort, pain, bad taste in mouth, diet modification, the use of analgesic and anxiety) except for xerostomia. Discomfort or swelling in the submandibular or parotid area over the last 3 years (2019 questionnaire) were present in 16% (26/162) of the patients against 29% (47/162) in 2013.



**Recurrent parotid abscess with associated stenosis**

*Miss Bethan Fon Jones (Consultant ENT Surgeon)*

*Wirral University Teaching Hospital, UK*

## **Introduction**

A 74-year-old lady with a history of CREST syndrome presents with symptoms of recurrent parotitis with numerous abscess formation.

## **Method and Results**

Ultrasound scanning confirmed chronic sialadenitis and sialectasis of the parotid gland; the main duct was dilated throughout with a suspicion of a 2.3mm calculus.

Sialendoscopy findings were of stagnant pus-like material on dilation of the papilla; there was chronic inflammation of the main duct extending beyond the hilum, slough throughout with associated stenosis of the proximal main duct. The ductal system was irrigated, the slough-like material was removed and the stenosed segment dilated.

16 months postoperatively, the patient remains asymptomatic with no further associated infections or abscess formation.

## **Conclusion**

Systemic sclerosis associated with CREST syndrome causes excessive dry mouth, resulting in salivary gland sialectasis and sialadenitis. Sialendoscopy has successfully treated this patient, eliminating the associated morbidity.



**MY EXPERIENCE IN SIALENDOSCOPY IN BRAZIL**  
Gabriela Robaskewicz Pascoto M.D.

## **Abstract**

**Introduction:** Sialendoscopy is a quite new procedure in Brazil. The first one was performed by Dr Francis Marchal and Dr Cláudio Cernea in São Paulo in 2011.

**Objective:** The aim of this speech is to share my experience in Brazil performing sialendoscopy since 2014 and acquire new knowledge to better treat patients.

**Results/Conclusion:** In these 5 years different diseases were treated using sialendoscopy such as stones, strictures with “idiopatic” causes, caused by Sjögren’s disease and by Juvenile Recurrent Parotitis (JRP). Patients submitted to radioiodine are also a recurrent cause of appointments and sialendoscopy is very useful.

Some pictures and videos will be shown to illustrate the class.



**Juvenile recurrent parotitis (JRP): how can sialendoscopy help?**



**Abstract:**

Juvenile recurrent parotitis is recurrent non suppurative parotitis in children. It is the second most common cause of parotitis in children. The etiology is not fully identified so far. It is usually self limited; however the recurrent episodes can be troublesome for the child and the family. The disease is characterized histologically by intraductal cystic dilatation with periductal lymphocytic infiltration.

Several lines of treatment have been suggested. However, traditional measures can control acute episodes but cannot affect frequency or severity of recurrences. We will present the role of sialendoscopy for diagnostic purposes together with ultrasonography and MRI Sialography and also for treatment of juvenile recurrent parotitis.



**Title:**

Assessing outcomes of Sialendoscopy for duct stenosis: our protocol and review of literature

Dr Sheelu Trivedi

Consultant ENT Surgeon

Bangalore, India.

Sialendoscopy has changed the way we approach Salivary gland pathologies and offer management options. As the indications of this procedure is increasing, so is the expectation of better outcomes. There is a need of documentation for counselling prospective patients and convincing insurance providers.

We discuss in this paper our beginners experience of the assessing patient outcomes in our Sialendoscopy Program for ductal stenosis.

There is surgeon's perspective of outcomes like clinical examination and ultrasound examination. These can be individual dependent and variable. Ultrasound based examination for ductal stenosis needs training and expertise.

We have reviewed the medical literature and would like to share perspective of published literature in our presentation.

Our initial assessment has shown that having a scoring system for patient pre and post -op helps to assess our outcomes in a scientific way.



TITLE: Treatment of scars in patients with chronic idiopathic sialadenitis-Our long time experience results

It is aimed to present the long-term outcomes and sialendoscopic findings in only patients with ductal scars in idiopathic chronic recurrent sialadenitis who experienced failure with conservative treatment and were treated with the sialendoscopy. The clinical and intraoperative data including the patient's age, sex, date of the procedure, which gland was an involved, operative finding and complications are going to be presented. Follow-up data is going to report whether the symptoms were resolved or recurred and whether any further procedures were performed. Sialendoscopy is a minimally invasive method for the diagnosis and treatment of ductal scars of the salivary gland after failure of conservative treatments in adults.

EVREN ERKUL

### **Parotid stenosis after facial plastic surgery**

Jeong-Seok Choi<sup>1</sup>, MD, Jae-Yol Lim<sup>2</sup>, MD

<sup>1</sup>Department of Otorhinolaryngology - Head and Neck Surgery, Inha University School of Medicine, Incheon, Republic of Korea

<sup>2</sup>Department of Otorhinolaryngology, Gangnam Severance Hospital, Yonsei University College of Medicine, Seoul, Republic of Korea

Corresponding authors:

Corresponding author: Jae-Yol Lim, MD, PhD

Department of Otorhinolaryngology-Head and Neck Surgery, Gangnam Severance Hospital, Yonsei University College of Medicine, 211, Eonju-ro, Gangnam-gu, Seoul 06273, Republic of Korea

E-mail: [jylimmd@yuhs.ac](mailto:jylimmd@yuhs.ac)

Tel: 82-2-2019-3468, Fax: 82-2-3463-4750

### **ABSTRACT**

Obstructive parotitis is one of the common diseases of the salivary gland and gives rise to pain and swelling of the involved parotid gland. This disorder results from sialolithiasis, duct stenosis, injury, or infection. Parotid ductal injury sometimes results from a complication of cosmetic surgery such as rhytidectomy, face-lift or zygomatic reduction. The leading causes of parotid gland injury due to facial cosmetic surgery are thought to be inadequate skills and scarce familiarity of the facial anatomy. Parotid ductal damage can cause the formation of fibrous tissue and can make ductal stenosis and obstruction of salivary flow and lead to secondary ascending infection. Recently, the symptoms of parotid stenosis may be ameliorated using a variety of new sialendoscopic procedures. This report presents an unusual parotid ductal injury after face-lift or zygomatic reduction. We report cases of obstructive parotitis which was formed by cosmetic surgical injury and parotitis treated successfully using sialendoscopic procedures. It is recommended that surgeons that perform facial cosmetic procedures should have full pieces of knowledge of the surgical anatomy of

the parotid region. When parotid gland damage is suspected after cosmetic surgery, a surgeon should transfer a patient to an otorhinolaryngologist who is good at performing sialendoscopy because sialendoscopy may be so useful for the management of obstructive parotitis.



**Parotid duct stricture complicated by a huge sialocele following facial cut wound: An imaging review**  
**Presenter: Hesham Zoheir, EGYPT.**

### **Abstract**

MRI sialography has proven to be highly valuable in accurate assessment of obstructive pathology of the salivary ductal system.

Hereby, a 29 year old male patient with history of left sided facial cut wound managed surgically. Following the procedure, the patient presented with gradual sizable tense swelling of the left side of the face.

Ultrasound showed the swelling to be cystic in nature and repeated aspirations were done with repeated recurrence of the swelling.

MRI sialography was performed revealing the cystic swelling to be originating from the left Stensen's duct due to combined stricture and ductal tear. It also showed accurate mapping of the described pathologies. Interesting imaging results will be presented in details.



Parotid stricture in a child  
Megan Hobson



**Abstract**

**Background:** Radioiodine therapy has been widely used for thyroid disease patients, but hyposalivation and xerostomia may occur in 10~30% of patients. Sialocentesis is a procedure that removes inflammatory substances in the salivary duct and expands the duct for the secretion and delivery of saliva. In this study, thyroid disease patients treated with radioactive iodine were selected among the patients with xerostomia who visited the hospital, and the effect of sialocentesis was compared and analyzed. And then, comparison between the radioiodine therapy-experienced group and the non-radioiodine therapy-experienced group was conducted.

**Results:** In this study, we studied xerostomia patients who underwent radioiodine therapy due to thyroid diseases and who underwent sialocentesis at the Korea University Anam Hospital. Sialocentesis is conducted by one surgeon. The study also compares the clinical symptoms before and after the surgery. After the procedure, the discomfort due to xerostomia was reduced, and the symptom was improved effectively.

**Conclusions:** The results of this study showed that sialocentesis has a clinical effect in the treatment of xerostomia, which is a side effect of radioiodine therapy. In addition, the possibility of further clinical application of sialocentesis in the future is found.

### **Key words**

Sialocentesis; Radioiodine; Submandibular gland; Sialendoscopy; Xerostomia

### **Versus a new questionnaire for evaluation SGD**

F. Boselie, S. Buchholzer, T. Lombardi, J. Seebach, F. Herrmann, L. Tchermissinof, F. Marchal

Xerostomia is considered as a subjective oral dryness symptom, which is common in the general population, with studies finding a prevalence between 8 and 13 %. Xerostomia is seen in many pathologies like Sjögren's Syndrome and xerostomia after radiation therapy, juvenile recurrent parotitis, IgG4 disease, and chronic sialadenitis caused by salivary stones or salivary strictures of unknown etiology. There has been a steady increase in the incidence of xerostomia due to radio-iodine treatment for thyroid cancer.

The only method to assess xerostomia is by oral dryness questionnaires (ODQ) which will assess the patient's quality of life. The first questionnaire assessing xerostomia was described by Guy in 1976 and from then until 2019, over a hundred oral dryness questionnaires have been published in the literature. The multiplicity of questionnaires and the absence of consensus regarding the use of a particular one, suggest that there is a need for a global questionnaire aiming to assess all salivary pathologies. Xerostomia is not an isolated symptom and patients often complain of pain and swellings, linked or not with meals, which is the reason why a questionnaire that looks at all of these surrounding symptoms was deemed necessary.

The aim of this presentation is to introduce a new questionnaire, elaborated in agreement with the Multidisciplinary Salivary Gland Society, and the first results of using it to evaluate healthy subjects and salivary gland patients.



Dubai Congress. CHOSSEGROS C. lectures

2. The fast puncture technique in submandibular sialendoscopy

Chossegros C, Graillon N, Le Roux MK, Marty P

Oral & Maxillofacial Department, Conception University Hospital. 147 bd Baille 13005 Marseilles, France. [cchossegros@ap-hm.fr](mailto:cchossegros@ap-hm.fr)

Introduction.

The papilla crossing is often a challenge in submandibular sialendoscopy. Sometimes, the papilla cannot be entered and the sialendoscopy should sometime be stopped. A retropapillary approach has been described to enter the duct behind the papilla to continue the sialendoscopy (Aldosari). A simpler alternative of retropapillary approach is the fast puncture technique

Technical Note

After infiltration, the duct is punctured just 5mm behind the papilla with a 21 Gage needle. A saline solution is injected through this puncture. The issue of the solution through the papilla confirms the intraductal position of the catheter. A 0.6 mm guide wire is gently inserted through the catheter into the duct. Following, the guide wire a bougie can dilate the ductal opening and give access to the sialendoscope, which is also inserted on the guide wire, allowing the sialendoscopy.

Conclusion. In difficult submandibular papilla, the fast puncture technique can help to facilitate the sialendoscopy

Pouzoulet P et al. Management of the submandibular duct papilla and other approaches to salivary ducts. In Witt, Surgery of the Salivary Glands, 2020. Elsevier

## ABSTRACT

### TRANSORAL ROBOTIC SUBMANDIBULAR SIALADENECTOMY (TORSS)

**Pasquale Capaccio**<sup>1</sup>; MD, Filippo Montevercchi<sup>2</sup>; MD, Giuseppe Meccariello<sup>2</sup>; MD, Giovanni Cammaroto<sup>2</sup>; MD; Jeffery Scott Magnuson<sup>3</sup>, MD; Claudio Vicini<sup>2</sup>, MD.

<sup>1</sup> Department of Biomedical, Surgical and Dental Sciences – University of Milan - Fondazione IRCCS Ca' Granda Ospedale Maggiore Policlinico, Milan, Italy

<sup>2</sup> Head and Neck Department, ENT & Oral Surgery Unit, G.B. Morgagni – L. Pierantoni Hospital of Forlì

<sup>3</sup> Florida Hospital, Celebration, FL, USA

Traditional removal of the submandibular gland is done through a transcervical approach; new proposals have come into the scientific limelight such as endoscopy-assisted transcervical sialadenectomy or (robot-assisted) submandibular sialadenectomy through a postauricular facelift transcervical approach. Transoral submandibular sialadenectomy has been described in the past, but with the advent of transoral robotic surgery, the proposal of removing the submandibular gland from the oral floor is gaining strength. A transoral robotic submandibular sialadenectomy by the Si Da Vinci Surgical Robot was performed in a 68 years' old female patient under general anaesthesia. The transoral robotic procedure was successful with no major postoperative complications and the patient was discharged on postoperative day 2. A mild tingling of the tip of the tongue was described by the patient three months after the procedure. The surgical time took 110 minutes (100 min for robotic time). No residual submandibular gland was observed at six months ultrasonographic follow-up evaluation. The transoral robotic submandibular sialadenectomy seems to be, with selective indication based on clinical and radiological assessment, a viable and safe alternative to traditional management in patients who refuse a cervical scar and the risk of paralysis of the facial nerve.



### **Usefulness of vascular sheaths in sialendoscopy**

Vascular sheaths are devices normally employed in interventional radiology and hemodynamics. They provide access to vascular lumen in a safe and easy way based on Seldinger technique.

In sialendoscopy these devices have different applications; they can be used as dilatation system in the papilla at the start of the procedure or in stenosis. They also provide a stable access port when we need to go repeatedly in and out during the procedure as in endoscopic lithotripsy. Finally, sheaths are very useful too in combined approaches; they facilitate the ductal dissection and the localization of the obstruction in transoral and transfacial approaches.

## **PREOPERATIVE PREPARATION THAT AVOIDS PROBLEMS DUE TO PUNCTUM LOCALIZATION DURING SIALENDOSCOPY UNDER GENERAL ANESTHESIA**

**Ozcelik N.; Altin G.**

### **ABSTRACT**

**INTRODUCTION:** Sialendoscopy is a method that has completely changed the approach to obstructive diseases of the salivary glands. This procedure is considered to represent a potential replacement for current treatment methods applied for stenosis of the salivary ducts or salivary stones.

**OBJECTIVES:** The most important and problematic part of the sialendoscopy method is the localization of the duct opening under general anesthesia. The aim of our study is to provide an easy solution for this problem with a simple preparation step performed before the patient is taken into the operating room.

**METHODS:** The study included 83 patients due to postbrandial swelling, tenderness, and pain in the region compatible with the anatomic locations of the salivary glands. These patients were diagnosed with stones in the salivary glands and underwent sialendoscopy. In 38 cases that underwent sialendoscopy, we used a loop or microscope under local anesthesia to isolate the entrance of the salivary gland ducts in the intervention room prior to general anesthesia. We placed a temporary stent, constructed from a pink color-coded i.v. cannula, into the duct.

**RESULTS:** The 38 cases that were treated with this method, due to non-localization of the punctum, did not require a switch to open surgery, localization of the duct by oral mucosal incision, or termination of the operation for patients who had not given the permission for gland resection. The time to access the stone was significantly shortened in the operating room.

**CONCLUSION:** Localization of the punctum is much easier whenever salivary secretions can be increased with stimuli. Using this physiological structure, a transient stent can be placed that significantly reduces the duration of the operation under general anesthesia and increases its safety.

## **A New Instrument in Sialendoscopy Set for Papillotomy "Guide Wire Chasing Scissors"**

**N. Ozcelik, G. Altin**

### **ABSTRACT**

#### **INTRODUCTION:**

Sialendoscopy is relatively a new procedure. Salivary gland canals are really challenging fields for surgery. New instruments are added to sialendoscopy set with the advancing technology.

#### **OBJECTIVES:**

While performing sialendoscopy, sometimes the canal can not be entered. At that time a "papillotomy" is needed. As a standart procedure, pin-ball ended scissors is used. Surgeon can enter the canal with the pin-ball end scissors, and can make papillotomy. Than the dilators are used to enlarge the oriffice. After the dilation, the endoscope is directed to the canal of salivary gland.

When the first cut is made, bleeding can cause losing of lumen at surgical field. Surrounding soft tissue may obliterate vision. Surgeon cannot continue the cutting procedure.

#### **METHODS:**

A new scissors is designed for this purpose. This scissors named as “guidewire chasing scissors” (patent pending) has a tiny pipe attached to its lower jaw. After entering the duct with guidewire, the wire is passed through the pipe attached to the lower jaw of specially designed scissors. By the help of guidewire, surgeon can be sure that the lower jaw is always in the canal. Cuts can be made without any suspicion of losing the track of duct. Marsupialisation of the duct can be made till the stone is reached.

#### **CONCLUSION:**

While performing sialendoscopy, after the first cut is made at surgical field, bleeding can cause losing the duct lumen. Surgeon cannot continue the cutting procedure. Surrounding soft tissue may obliterate vision.

Once the guide wire is placed, it is easy to make papillotomy with guidewire chasing scissors. The guidewire can be chased by the scissors till the stone is reached. Thinking about the oral base anatomy, the nerves and the vessels are deep to the salivary canal.

It is safe to make cuts when you are sure that you are “in the canal”, which means you are above the critical nerves and vessels.

This instrument can also be used for surgery of sinus tract marsupialisation in other fields of body.



#### **Treatment of multiple parotid strictures: Sialendoscopic double stenting**

Tobias Kleinjung<sup>1</sup>, Francis Marchal<sup>2,3</sup>

<sup>1</sup>Department of Otorhinolaryngology – Head and Neck Surgery, University Hospital Zurich,

<sup>2</sup>

<sup>2</sup>European Sialendoscopy Training Center, Cours de Rive, Geneva, Switzerland

<sup>3</sup>Department of Otorhinolaryngology – Head and Neck Surgery, University Hospital Geneva, Geneva, Switzerland

Strictures in the ductal system of parotid glands are one the most common causes of swelling or sialadenitis. We differentiate unique local strictures from multiple strictures. Assessment of strictures can be obtained by ultrasound, MRI sialography or diagnostic sialendoscopy. The classical treatment is stricture dilatation under vision followed by stenting of the duct.

However, if strictures are present in multiple branches there is a necessity of separate stenting to allow patency after dilatation and to avoid exclusion and postoperative swelling in the excluded parts of the parotid gland. We present a technique of a minimally invasive sialendoscopic procedure with visible dilatation of strictures and insertion of two silicone stents per side in the main branches of the ductal system. The correct position of the stents was controlled ultrasonographically. In the presented case, the stents were removed after two weeks. Two years the procedure the patient was mainly symptom-free with very rare and short-lasting swellings. Ultrasound revealed a stable situation of the dilated strictures.



